5. Danesh-Meyer H, Savino PJ, Gamble GG. Poor prognosis of visual outcome after visual loss from giant cell arteritis. *Ophthalmology*. 2005;112:1098-103.
6. Hayreh SS, Zimmerman B, Kardon RH. Visual improvement with corticosteroid therapy in giant cell arteritis. Report of a large study and review of literature. *Acta Ophthalmol Scand*. 2002;80:355-67.
7. Kale N, Eggenberger E. Diagnosis and management of giant cell arteritis: a review. *Curr Opin Ophthalmol*. 2010;21:417-22.
8. Hayreh S, Zimmerman B. Visual deterioration in giant cell arteritis patients while on high doses of corticosteroid therapy. *Ophthalmology*. 2003;110:1204-15.
9. Lee AG, Eggenberger ER, Kaufman DI, Manrique C. Optic nerve enhancement on magnetic resonance imaging in arteritic ischemic optic neuropathy. *J Neuroophthalmol*. 1999;19:235-7.
10. Morgenstern K, Ellis B, Schochet S, Lindberg J. Bilateral optic nerve sheath enhancement from giant cell arteritis. *J Rheumatol*. 2003;30:625-7.
11. Liu KC, Chesnutt DA. Perineural optic nerve enhancement on magnetic resonance imaging in giant cell arteritis. *J Neuroophthalmol*. 2013;33:279-81.
12. Liu TY, Miller NR. Giant cell arteritis presenting as unilateral anterior ischemic optic neuropathy associated with bilateral optic nerve sheath enhancement on magnetic resonance imaging. *J Neuroophthalmol*. 2015;35:360-3.
13. Kornberg MD, Ratchford JN, Subramaniam RM, Probasco JC. Giant cell arteritis mimicking infiltrative leptomeningeal disease of the optic nerves. *BMJ Case Rep*. 2015;2015.
14. D'Souza NM, Morgan ML, Almarzouqi SJ, Lee AG. Magnetic resonance imaging findings in giant cell arteritis. *Eye (Lond)*. 2016;30:758-62.
15. Chen JJ, Kardon RH, Daley TJ, Longmuir RA. Enhancement of the optic nerve sheath and temporal arteries from giant cell arteritis. *Can J Ophthalmol*. 2015;50:e96-7.

Can J Ophthalmol 2018;53:e236–e239
0008-4182/18/$-see front matter © 2018 Canadian Ophthalmological Society.
Published by Elsevier Inc. All rights reserved.
https://doi.org/10.1016/j.jcjo.2018.02.013

Swept source optical coherence tomography angiography in optic disc melanocytoma

Melanocytoma of the optic nerve head (ONH) is a benign pigmented hamartoma with rare malignant potential. Malignant transformation is seen in 1%–2% cases.[1] They may extend into the adjacent retina and the choroid.[2] Histopathologically, melanocytoma is composed of intensely pigmented round to oval nevus cells with benign features. Most cases are asymptomatic with no loss of visual acuity.[3,4] Diagnosis is based on ophthalmoscopic features. Ancillary tests such as ultrasonography and optical coherence tomography help in follow-up. Optical coherence tomography angiography (OCT-A) is a non-invasive imaging modality that can construct a map of blood flow in various layers using specialized algorithms.

The authors confirm adherence to the tenets of the Declaration of Helsinki. Written informed voluntary consent was taken. A 35-year-old male with no visual complaints was referred to our tertiary care centre for a mass lesion on the ONH. On examination the best-corrected visual acuity was 20/20 OU with unremarkable anterior segment examination. Fundus examination of the right eye showed an elevated hyperpigmented lesion on the ONH, 1.5 disc diameter, with feathery margins, involving two-third of the disc and extending superiorly into the adjacent retina. No choroidal extension was noted. The pigmentation was more at the margins with small areas of hyperpigmentation inferior to the mass on the ONH and the adjacent retina. A Telangiectatic vessel was seen on the surface of the mass. Large retinal vessels arising from the disc, macula, and peripheral fundus were within normal limits (Fig. 1). Left eye fundus was unremarkable. Ultrasonography showed a dome-shaped lesion arising from the optic disc with thickness of 3.42 mm with high internal reflectivity and orbital shadowing (Fig. 2). OCT showed an elevated ONH lesion with a hyper-reflective layer and optical shadowing behind it.

Fig. 1—Fundus photograph of the right eye showing an elevated hyperpigmented lesion covering two-third of the optic nerve head with ill-defined margins extending into the superior retina. Surface vascularity is visible.

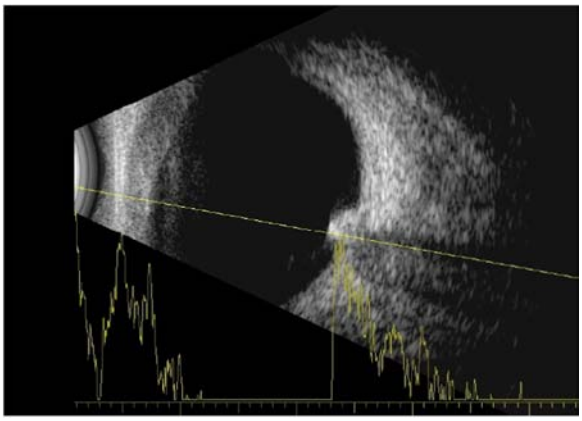

Fig. 2—B scan ultrasonography showing a small dome-shaped lesion arising from the optic disc with high internal reflectivity with orbital shadowing.

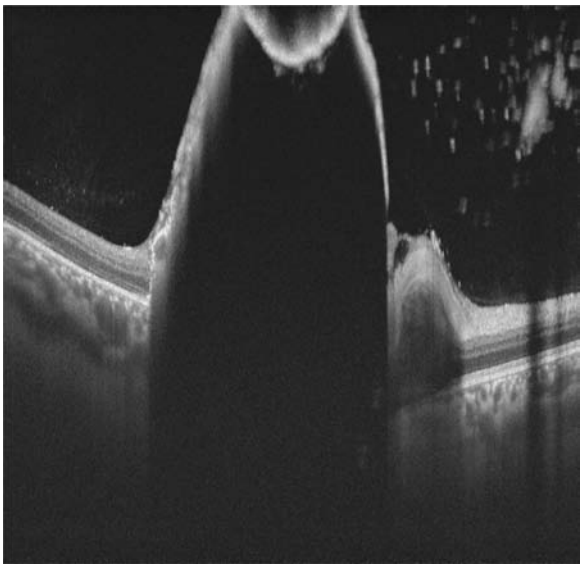

Fig. 3—Swept source optical coherence tomography image showing gradual transition from normal retina into the mass. An elevated optic nerve head lesion can be seen with hyperreflective edges and optical shadowing behind it. Vitreous opacities are noted.

Vitreous opacities were also noted (Fig. 3). These findings were suggestive of ONH melanocytoma.

The OCT-A of the ONH melanocytoma showed heterogeneously distributed sparse vasculature intrinsic to the mass with a prominent vessel seen in the centre of the lesion corresponding to the one seen on the clinical photograph (Fig. 4). The areas of attenuated signals may indicate absence of vascularity or very densely packed cells. Obscuration of the large vessels by the mass both at the level of ONH and choroid may signify the posterior extent of the tumour.

The patient was explained about the nature of lesion and asked to follow-up every 6 months.

Melanocytoma of the ONH is a benign pigmented hamartoma with rare malignant potential of 1%–2%.[1] They may extend into the adjacent retina and the choroid.[2] In a study by Joffe et al., 18% of patients presented with lesion confined to the ONH, 77% extending into the retina, and 47% have juxtapapillary choroid component.[5] In most cases they are asymptomatic and do not interfere with visual acuity.[6] Mild vision loss can be seen in around 25% of cases.[7] Visual loss can occur due to macular subretinal fluid, central retinal vein occlusion, or ischemic optic neuropathy and optic atrophy, due to compression by tumour.[3,4] They show slow growth in approximately 11% of cases.[7] A study by Lee et al. revealed tumour growth of 0% at 1 year, 14% at 5 years, and 57% at 8 years.[8] Increased tumour thickness, presence of intrinsic vascularization, and nodular configuration are the 3 parameters used to stratify lesions into low-risk or high-risk for malignant transformation.[2] In this case, intrinsic tumour vascularity with a thickness of 3.42 mm was present, making it high risk for tumour growth. Hence, close follow-up was advised.

Growth and visual loss do not always imply malignant transformation and such changes can occur from ischemic necrosis in the lesion.[1] The characteristic features of

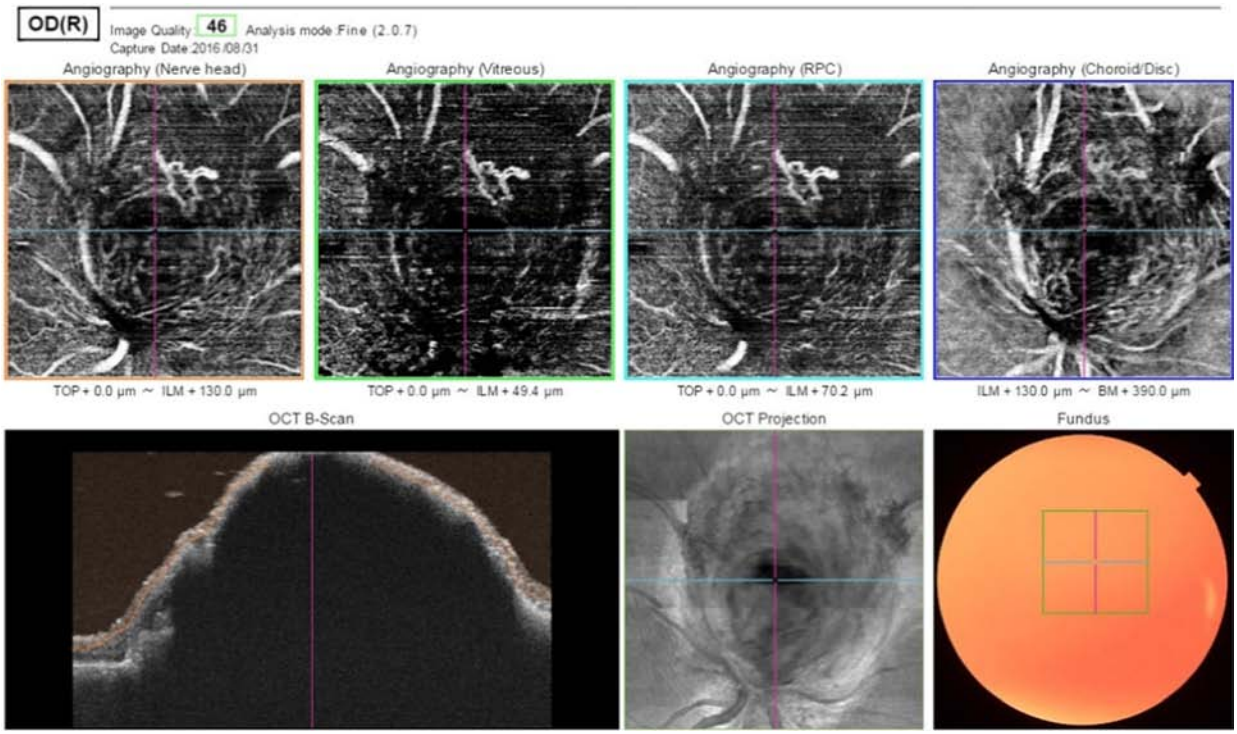

Fig. 4—Optical coherence tomography angiography showing heterogeneously distributed sparse intrinsic vasculature. A central loop of vessel can be clearly made out at all levels. The areas of attenuated signals may indicate absence of vascularity or very densely packed cells.

malignant transformation are an initial lesion originating exclusively from optic nerve without juxtapapillary choroidal involvement, with progressive growth and visual loss.[1] Genetic expression profiling is a newer technique described to assess the prognosis. Fine-needle aspiration biopsy of the tumour through a transvitreal route is required to obtain tissue sample for genetic profiling.[9]

Diagnosis is mainly based on the clinical features. Ancillary tests help in characterizing the lesion morphologically and follow-up.

Ultrasonography is useful in detecting the tumour when the tumour elevation is more than 0.5 mm.[1] Gologorsky et al. described the ultrasonographic features of melanocytoma of ONH in which 62% patient had dome-shaped elevation and 90% had medium to high reflectivity.[10] In this case, the ultrasonography revealed a dome-shaped elevation with high internal reflectivity with posterior shadowing.

OCT of melanocytoma has been described as a mass with hyper-reflectivity at its anterior surface and dense posterior shadowing with an optically empty appearance.[10] Similar features were seen in this case. Presence of vitreous opacities have been reported in 4%–13% of cases and do not signify malignancy.[6,11] This case also showed presence of vitreous opacities. OCT does not reveal the internal properties of the tumour due to dense shadowing.[10]

Previous studies have described melanocytomas as avascular tumours with hypofluorescence throughout all the phases of fluorescein angiography because of blocked fluorescence by the pigmented tumour mass.[7,12] OCT-A, however, reveals the tumour vascularity irrespective of the pigmentation as it uses motion of red blood cells against static tissue as intrinsic contrast. It compares the split spectrum amplitude decorrelation signal between sequential B scans taken at precisely the same cross section in order to construct a map of blood flow. Artefacts produced by axial bulk motion from patient movement are eliminated by postimaging software. In this case, OCT-A showed presence of heterogeneously distributed small vessels within the tumour mass with a prominent central shunt vessel. Detection of superficial tumour vascularization by OCT-A has also been described by Carnevali et al.[13]

Hence OCT-A might serve as a noninvasive tool to ascertain tumour vascularity at different levels of the tumour that might not be picked up on fluorescein angiography and OCT or both combined. However, close follow-up is required to detect tumour growth, if any, to confirm malignant transformation.

Acknowledgment: The optical coherence tomography angiography machine (DRI OCT Triton) was acquired through an academic grant from the Indo-German Science and Technology Centre, Gurugram, National Capital Territory, India.

Astha Jain, MS, Thirumalesh MB, MD, Bhujang K. Shetty, MS
Narayana Nethralaya Eye Hospital, Bangalore, India.

Correspondence to:
Astha Jain: astha2jain@gmail.com

References

1. Shields JA, Demirci H, Mashayekhi A, Eagle RC, Shields CL. Melanocytoma of optic disc: a review. *Surv Ophthalmol*. 2006;51:93-104.
2. Mohmad Z, Kah TA, Yong KC, Halim WH, Yong TK. Melanocytoma of the optic nerve head-a diagnostic dilemma. *Clin Pract*. 2011;1:60.
3. Al-Rashaed S, Abboud EB, Nowilaty SR. Characteristics of optic disc melanocytomas presenting with visual dysfunction. *Middle East Afr J Ophthalmol*. 2010;17:242-5.
4. Usui T, Shirakashi M, Kurosawa A, Abe H, Iwata K. Visual disturbance in patients with melanocytoma of the optic disk. *Ophthalmologica*. 1990;201:92-8.
5. Joffe L, Shields JA, Osher RH, Gass JD. Clinical and follow-up studies of melanocytomas of the optic disc. *Ophthalmology*. 1979;86:1067-83.
6. Shields JA, Shields CL, Eagle RC, Singh AD, Berrocal MH, Berrocal JA. Central retinal vascular obstruction secondary to melanocytoma of the optic disc. *Arch Ophthalmol*. 2001;119:129-33.
7. Shields JA, Demirci H, Mashayekhi A, Shields CL. Melanocytoma of optic disc in 115 cases: the 2004 Samuel Johnson Memorial Lecture, part 1. *Ophthalmology*. 2004;111:1739-46.
8. Lee CS, Bae JH, Jeon IH, Byeon SH, Koh HJ, Lee SC. Melanocytoma of the optic disk in the Korean population. *Retina*. 2010;30:1714-20.
9. Alba MA, Villegas VM, Gold AS, et al. Clinical findings and genetic expression profiling of three pigmented lesions of the optic nerve. *Case Rep Ophthalmol Med*. 2015;2015:590659.
10. Gologorsky D, Schefler A, Ehlies FJ, et al. Clinical imaging and high-resolution ultrasonography in melanocytoma management. *Clin Ophthalmol*. 2010;4:855-9.
11. Shields CL, Perez B, Benavides R, et al. Optical coherence tomography of optic disk melanocytoma in 15 cases. *Retina*. 2008;28:441-6.
12. Rubin ML. Disciform lesion overlying melanocytoma simulating progression of choroidal melanoma. *Trans Am Ophthalmol Soc*. 1976;74:282-94.
13. Carnevali A, Querques L, Zucchiatti I, Scorcia V, Bandello F, Querques G. Optical coherence tomography angiography features in melanocytoma of the optic nerve. *Ophthalmic Surg Lasers Imaging Retina*. 2017;48:364-6.

Can J Ophthalmol 2018;53:e239–e241
0008-4182/18/$-see front matter © 2018 Canadian Ophthalmological Society.
Published by Elsevier Inc. All rights reserved.
https://doi.org/10.1016/j.jcjo.2018.01.038

Inflammatory myofibroblastic tumour presenting as a medial eyelid mass in a child

Inflammatory myofibroblastic tumour (IMT) is a rare tumour of mesenchymal origin that was originally identified as a pulmonary growth in children but has been reported in many different organ systems, including rare cases of orbital IMT. Local growth and recurrence of IMTs can affect both the structure and function of the affected organ system, and rarely the lesion may metastasize or have low-grade malignant transformation into a sarcoma.[1]