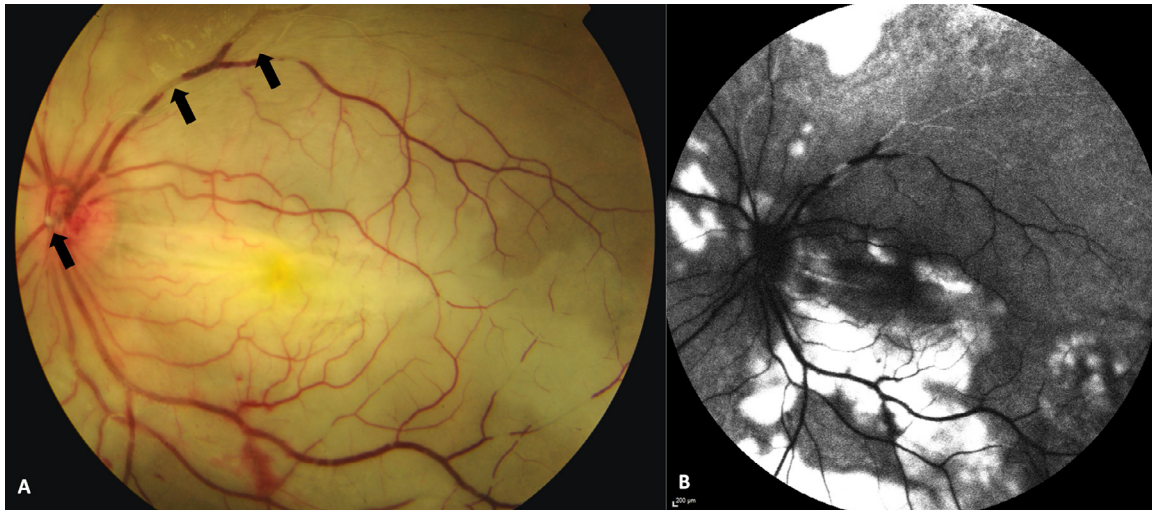


## Ophthalmic artery occlusion after dermal fillers injection



A young female patient developed left-sided headache, periorbital pain, and acute loss of vision within a few minutes after receiving left-sided nasal hyaluronic acid dermal fillers. Visual acuity of her left eye was no light perception, with a grade 4 relative afferent pupillary defect. Posterior segment examination revealed marked edema of the posterior pole with absence of cherry-red spot, suggestive of an iatrogenic ophthalmic artery occlusion. Multiple emboli (A, arrows) were seen within the central retinal artery and branching arterioles. Fundus fluorescein angiography (B) showed delayed arm-retina time, absence of choroidal flush, and nonperfusion of central retinal artery.

Zhi Hong Toh,\*

John Tsia-Chuen Kan,\*

Chee Chew Yip<sup>†</sup>

\*Department of Ophthalmology, National Healthcare Group Eye Institute, Tan Tock Seng Hospital, Singapore, Singapore;

<sup>†</sup>Department of Ophthalmology and Visual Sciences, Khoo Teck Puat Hospital, Singapore, Singapore

Originally received Apr. 21, 2020. Final revision May. 30, 2020. Accepted Jun. 3, 2020.

Correspondence to. E-mail: [tohzhihong@gmail.com](mailto:tohzhihong@gmail.com), [zhihong.toh@mohh.com.sg](mailto:zhihong.toh@mohh.com.sg).

### Author Statement

Zhi Hong Toh: Writing - Original Draft

John Tsia-Chuen Kan: Writing - Review & Editing

Chee Chew Yip: Supervision

### Footnotes and Disclosure

The authors have no proprietary or commercial interest in any materials discussed in this article.

## Retinal involvement in severe noncerebral malaria

